

# Disappearing Cerebral Microbleed After A Lacunar Infarct.

Oscar H. Del Brutto, MD<sup>1,2</sup>

---

## Abstract

Both, lacunar infarcts and deep cerebral microbleeds are recognized markers of cerebral small vessel disease. However, the “de novo” appearance of an infarct at the site of a previously documented microbleeds has not been described. Here, we report a patient who suffered a lacunar infarct at the site of a microbleed, associated with its disappearing on MRI. This case illustrate a previously unrecognized progression of a cerebral microbleed, which may help to elucidate pathogenetic mechanisms involved in this uncommon evolution.

**Keywords:** Cerebral microbleed; lacunar infarct; arteriolopahy; lipohyalinosis.

## Resumen

Tanto los infartos lacunares como los microsangrados son marcadores muy reconocidos de enfermedad cerebral de pequeño vaso. Sin embargo, la aparición de un infarto en el sitio donde se localizaba un microsangrado no ha sido documentada. En el presente reporte se describe un paciente que sufrió un infarto lacunar en el mismo sitio donde se había previamente documentado un microsangrado. Este caso ilustra esta novel progresión de un microsangrado, la cual puede ayudar a dilucidar los mecanismos etiopatogénicos implicados en esta evolución.

**Conflicts of interest:** Nothing to disclose.

**External funding:** This study was partially supported by Universidad Espíritu Santo – Ecuador, Guayaquil – Ecuador.

Rev. Ecuat. Neurol. Vol. 23, N° 1-3, 2014

---

## Introducción

Microbleeds (MB) located deep in the brain (infratentorial and basal ganglia) have been associated with arteriosclerotic vasculopathy and are often seen in patients with ischemic or hemorrhagic strokes.<sup>1</sup> Some case-reports have shown the occurrence of intracerebral hemorrhages at the site of a previously documented MB, as a reflection of a bleeding-prone vasculopathy.<sup>2,3</sup> To our knowledge, occurrence of a cerebral infarct at the site of a previously recognized MB has not been described. Here, we report a patient who suffered a lacunar infarct at the site of a MB, associated with its disappearing on MRI.

## Case report

A 67-year-old man with history of arterial hypertension was first evaluated on June 2012, because of a left pure motor hemiparesis related to a lacunar infarct in the pons. At that time, the MRI showed, besides the pontine infarct, bilateral white matter hyperintensities of presumed vascular origin and a single MB in the posterior limb of the left internal capsule (Figure, upper panel).

A transthoracic echocardiogram revealed left ventricle hypertrophy. MRA of intracranial vessels and Doppler examination of extracranial arteries did not reveal any abnormalities. He was discharged a few days later on aspirin and anti-hypertensive therapy; the motor deficit gradually improved and six months later he returned to his job as a carpenter. He remained well until February 2014, when he was re-admitted to the hospital because of the sudden onset of a syndrome of ataxic hemiparesis in the right side of the body. MRI showed a corresponding lacunar infarct located in the posterior limb of the left internal capsule, at the site where the MB was seen two years ago; the MB was no longer visible on the repeated gradient-echo sequence (Figure, lower panel).

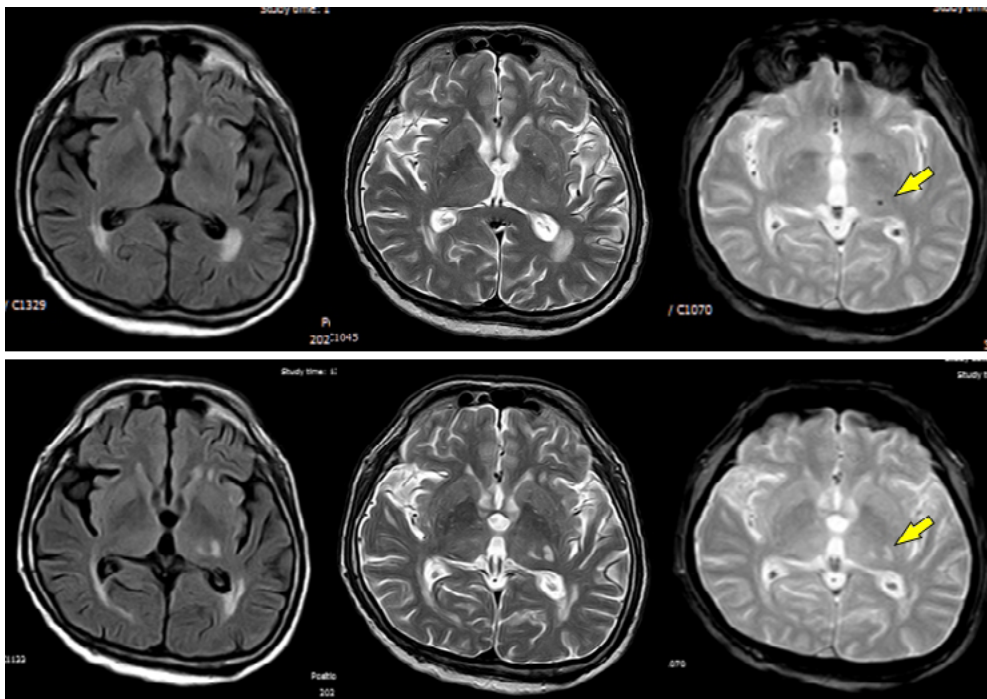
## Comment

In this patient, the initial lesion appeared as a true MB on MRI and not as a MB-mimic because of its size, shape and signal properties (visible only on the gradient echo sequence).<sup>4</sup> Histopathological studies have shown that most MRI-recognized deep MB are formed by hemo-

---

<sup>1</sup>School of Medicine, Universidad Espíritu Santo – Ecuador, and  
<sup>2</sup>Department of Neurological Sciences, Hospital-Clínica Kennedy, Guayaquil, Ecuador.

Correspondence  
Oscar H. Del Brutto, MD. Air Center 3542, PO Box 522970, Miami, FL 33152-2970.  
Email: oscardelbrutto@hotmail.com



**Figure 1.** Upper panel: MRI (FLAIR, T2-weighted and gradient-echo sequences) on first admission showing a microbleed in the posterior limb of the internal capsule. Lower panel: same sequences of MRI taken on second admission showing a lacunar infarct in the region where the microbleed was located and disappearance of the microbleed (arrow)

siderin-laden macrophages resulting from extravasation of blood components through vessel walls affected by lipofibrohyalinosis.<sup>5</sup> It might happen that these already damaged vessels occlude, leading to a lacunar infarct in the region of the MB; in these cases, it should not be expected for the MB to disappear after the infarct. In the current report, disappearance of the MB suggest that it was related to a patent small-vessel micro-dilatation filled with partially stagnant blood that could not be longer supplied when the parent vessel was occluded. This finding might correspond to the microaneurysms originally recognized by Charcot and Bouchard and further described in detail by C.M. Fisher.<sup>6</sup> Before the widespread availability of MRI, a single case report showed histopathological evidence of the occurrence of a lacunar infarct in the pons related to thrombosis of a microaneurysm located in the parent vessel,<sup>7</sup> providing further support to our assumption.

In summary, this case illustrate a previously unrecognized evolution of a cerebral MB. Further longitudinal studies of patients with MRI-recognized deep MB must focus on the occurrence of new lacunar infarcts at the site of previously detected MB to see if their occurrence is associated with persistence or disappearance of the MB. This would provide more insights on the pathogenesis of this increasingly recognized form of “silent” marker of small vessel disease.

## References

1. Kim BJ, Lee SH. Cerebral microbleeds: their associated factors, radiologic findings, and clinical implications. *J Stroke* 2013;15:153-163.
2. Knottnerus ILH, van Oostenbrugge RJ, Lodder J. Intracerebral hematoma at a microbleed site in two lacunar stroke patients on antithrombotic therapy. *J Neurol* 2008;255:1254-1255.
3. Vernnoij MW, Heeringa J, de Jong GJ, van der Lugt A, Breteler MMB. Cerebral microbleed preceding symptomatic intracerebral hemorrhage in a stroke-free person. *Neurology* 2009;72:763-765.
4. Wardlaw JM, Smith EE, Biessels GJ, Cordonnier C, Fazekas F, Frayne R, et al. Neuroimaging standards for research into small vessel disease and its contribution to ageing and neurodegeneration. *Lancet Neurol* 2013;12:822-838.
5. Shoamanesh A, Kwok CS, Benavente O. Cerebral microbleeds: histopathological correlation of neuroimaging. *Cerebrovasc Dis* 2011;32:528-534.
6. Fisher CM. Cerebral military aneurysms in hypertension. *Am J Pathol* 1972;66:313-330.
7. Benhaïem-Sigaux N, Gherardi R, Salama J, Gray F, Amouroux J, Poirier J. Thrombosis of a saccular microaneurysm causing cerebral (pontine) lacunae. *Acta Neuropathol (Berl)* 1986;69:332-336.