

# “Brain Holes.” A Diagnostic Challenge In Cysticercosis-Endemic Areas.

Oscar H. Del Brutto, MD<sup>1,2</sup>

## Abstract

The introduction of modern neuroimaging and immunologic techniques has increased the diagnostic accuracy for neurocysticercosis. However, there are some conditions that mimic neurocysticercosis by the time of the initial evaluation of the patient. We present six patients with a single abnormally dilated perivascular Virchow-Robin space mimicking a cysticercus. In such cases, administration of repeated trials of cysticidal drugs together with long-term follow-up observation, excluded the diagnosis of neurocysticercosis. Physicians working in cysticercosis-endemic areas must keep in mind the possible occurrence of a single dilated perivascular space, to avoid the practice of unnecessary invasive procedures in patients with “cysticerci-like” lesions that do not change after several courses of cysticidal drug therapy.

**Keywords:** Cysticercosis; neurocysticercosis; perivascular spaces; Virchow-Robin space

## Resumen

La introducción de modernos equipos de neuroimagen y de técnicas inmunológicas confiables ha facilitado el diagnóstico de la neurocisticercosis. A pesar de estos avances, existen condiciones que simulan neurocisticercosis al momento de la evaluación inicial de algunos pacientes. En el presente artículo se reportan seis pacientes con un espacio perivascular de Virchow-Robin exageradamente dilatado, que simuló clínica y radiológicamente un cisticerco. En estos casos, la administración repetida de drogas cisticidas y la observación a largo plazo, excluyó el diagnóstico de neurocisticercosis. Los médicos que trabajan en áreas endémicas deben considerar esta posibilidad diagnóstica para evitar la práctica de procedimientos invasivos innecesarios en pacientes con este tipo de lesiones, que no responden luego de cursos repetidos de terapia cisticida.

**Conflicts of interest:** Nothing to disclose.

**External funding:** This study was partially supported by Universidad Espíritu Santo – Ecuador, Guayaquil – Ecuador.

Rev. Ecuat. Neurol. Vol. 23, N° 1-3, 2014

## Introduction

The introduction of modern neuroimaging and immunologic techniques has increased the diagnostic accuracy for neurocysticercosis.<sup>1</sup> However, the high number of false-negative results that occur with the immunoblot in patients with a single intracranial cysticerci and the lack of specificity of some CT and MRI findings, may create confusion when immunological or neuroimaging data alone is used to confirm or exclude the disease. A set of diagnostic criteria for neurocysticercosis has been helpful to enhance our diagnostic accuracy for this parasitic disease by allowing the objective evaluation of clinical, radiological, immunologic, and epidemiologic data.<sup>2</sup> Even after proper interpretation of these criteria, there are some conditions that mimic neurocysticercosis by the time of the initial evaluation of the patient. It is just in these cases, where a therapeutic trial with cysticidal drugs and long-term follow-up may help to confirm or exclude the disease. Here, we present six patients with a single abnormally di-

lated perivascular Virchow-Robin space mimicking a cysticercus. In such cases, administration of repeated trials of cysticidal drugs together with long-term follow-up observation, excluded the diagnosis of neurocysticercosis.

## Case Reports

Patients were two men and four women with ages ranging from 8 to 64 years. Three had chronic history of recurrent seizures, two complained of headache, and the other presented with mild cognitive decline. They were referred to our institution with the diagnosis of “neurocysticercosis resistant to cysticidal drugs”. All patients had a normal neurological examination, a negative serum immunoblot test for detection of anticysticercal antibodies, and normal results of the cytochemical analysis of CSF. Neuroimaging studies showed—in all cases—a single round or oval-shaped cystic lesion, measuring more than 15mm in diameter, located at the subcortical white matter of ce-

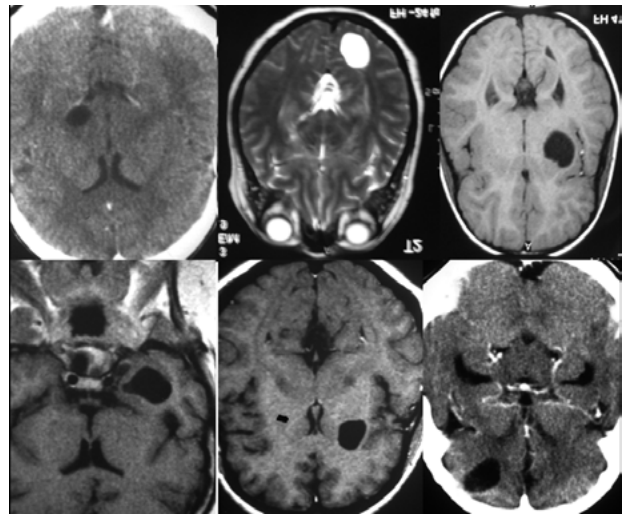
<sup>1</sup>School of Medicine, Universidad Espíritu Santo – Ecuador, and  
<sup>2</sup>Department of Neurological Sciences, Hospital-Clinica Kennedy, Guayaquil, Ecuador.

Correspondence  
Oscar H. Del Brutto, MD. Air Center 3542, PO Box 522970, Miami, FL 33152-2970.  
Email: oscar-delbrutto@hotmail.com

rebral hemispheres in three patients, the basal ganglia in two, and the thalamus in one. Lesions were hypodense on CT and had the same intensity of CSF in all the sequences of MRI (Figure 1). Lesions were sharply demarcated from the surrounding brain tissue, were not surrounded by edema, and did not show internal brilliant dots nor abnormal enhancement after contrast medium administration. All patients had been treated with albendazole (15 mg/kg/day for one to two weeks), and the three patients with seizures also received antiepileptic drugs. Control neuroimaging studies after three to six months of that initial trial showed no changes in the size or shape of the lesions. After admission to our hospital, all received praziquantel (50 mg/kg/day for 15 days). Again, control neuroimaging studies performed from three to six months after praziquantel therapy, did not show any change in the lesions. Patients had been followed for at least two years after the end of the second course of cysticidal drug therapy, and repeated neuroimaging studies by that time showed no changes in the size or shape of the lesions.

### Discussion

Abnormally enlarged Virchow-Robin spaces are a common finding in both children and adults, and may occur in otherwise healthy persons or may be associated with a number of degenerative diseases or congenital malformations of the nervous system.<sup>3,4</sup> In almost most cases, such spaces take a honeycomb-like appearance and may be easily recognized on MRI. However, in some other cases, they appear as huge cystic lesions resembling other conditions such as brain tumors.<sup>5,6</sup> Enlargement of a single Virchow-Robin space having the appearance of a “brain hole” has rarely, if ever, been reported. It is in those cases that neurocysticercosis could be erroneously diagnosed, particularly if the patient comes from an area endemic for this parasitic disease. A trial with cysticidal drugs may help to solve this diagnostic challenge, by favoring the disappearance of cysticerci-related lesions. It could be argued that the lack of changes after a therapeutic trial does not necessarily mean that these lesions were not cysticerci, since some cysts may not respond to albendazole. These patients, however, received both albendazole and praziquantel in a sequential order, and also were followed-up for at least two years after the second trial of therapy. It is unlikely that single parenchymal brain cysticercus did not disappear or even changed in size after this approach.<sup>1</sup> Moreover, most of the lesions presented here had at least one straight side and beveled border, which are not seen in cysticerci.



**Figure 1.** Single dilated perivascular Virchow-Robin spaces mimicking cysticerci in six patients.

In conclusion, physicians working in cysticercosis-endemic areas as well as in places where cysticercosis is increasingly recognized such as the Western European territory,<sup>7</sup> must keep in mind the possible occurrence of single dilated perivascular spaces, to avoid repeated courses of cysticidal drugs or unnecessary invasive procedures in patients with “cysticerci-like” lesions who do not respond to several courses of cysticidal drug therapy.

### References

1. Del Brutto OH. Neurocysticercosis. *Continuum (Minneapolis)* 2012;18:1392-1416.
2. Del Brutto OH, Rajshekhar V, White AC Jr, et al. Proposed diagnostic criteria for neurocysticercosis. *Neurology* 2001;57:177-183.
3. Rollins NK, Deline C, Morriss MC. Prevalence and clinical significance of dilated Virchow-Robin spaces in childhood. *Radiology* 1993;189:53-57.
4. Zhu YC, Dufouil C, Mazoyer B, et al. Frequency and location of dilated Virchow-Robin spaces in elderly people: a population-based 3D MR imaging study. *AJNR Am J Neuroradiol* 2011;32:709-713.
5. Kwee RM, Kwee TC. Virchow-Robin spaces at MR imaging. *Radiographics* 2007;27:1071-1086.
6. Chudy D, Rados M, Ozretic D, Grahovac G, Zarkovic K. Stereotactically treated giant perivascular spaces in a 13-year-old boy mimicking brain tumor. *Cen Eur Neurosurg* 2011;72:104-106.
7. Del Brutto OH. Neurocysticercosis in Western Europe: a re-emerging disease? *Acta Neurol Belg* 2012;112:335-343.